



**RESENTING CLINICAL SIGNS**

History: Suspect mild cardiomegaly in radiographs.

DATE

4/14/23

**ECHOCARDIOGRAPHIC FINDINGS**

2D, M-mode, and Doppler study.

PERFORMED BY:

Val Shumskaya

Left atrial size is normal. The mitral valve is normal. Left ventricular wall thickness is normal. Left ventricular internal dimensions are normal. Left ventricular systolic function is normal. The aorta and aortic valve are normal. Right atrial and right ventricular dimensions are normal. The tricuspid valve is normal. The pulmonary artery and pulmonic valve are normal. No shunting lesions are visualized. No pericardial effusion or cardiac masses are seen.

INTERPRETED BY

Keith Blass, DVM,  
MS, DACVIM  
(Cardiology)

LA - 38.5 mm  
IVSd - 8.8 mm  
LVPWd - 8.8 mm  
LVIDd - 35.8 mm  
LVIDs - 24.3 mm  
FS - 32%  
RA - 25.8 mm  
LVOT - 1.43 m/s  
RVOT - 1.00 m/s

PATIENT

Ozzy Silverstein

**ASSESSMENT/RECOMMENDATIONS**

Normal echocardiogram

SPECIES

Canine

This examination demonstrates no evidence of structural heart disease. While I agree that Ozzy's cardiac silhouette is enlarged in his radiographs, I suspect that this is a normal variant/artifactual, as no evidence of cardiac dysfunction or chamber enlargement is present in her echocardiogram.

BREED

No therapy is recommended based on this exam.

Aussie Mix

A recheck echocardiogram is recommended if new physical exam and/or clinical abnormalities suggestive of the presence of cardiac dysfunction develop.

SEX

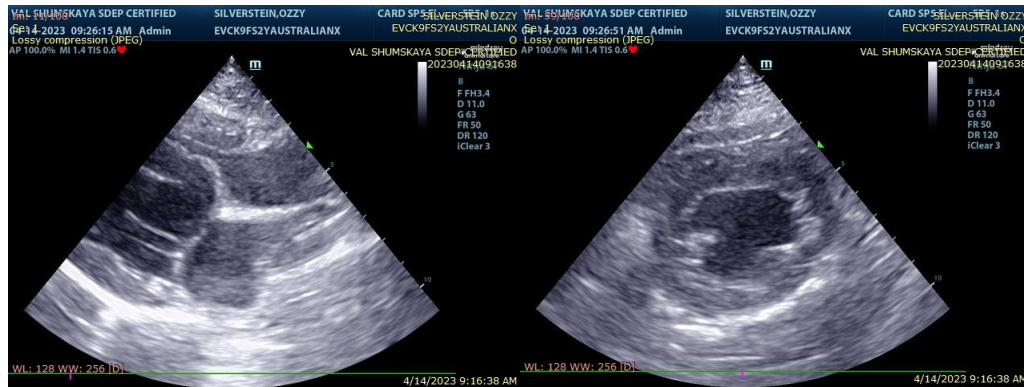
FS

AGE

2 y

WEIGHT

62.2 lb



HOSPITAL NAME

Englewood VC

The information and recommendations provided are based on the images presented by the referring veterinarian. No evaluation can be communicated regarding pathology that was not visible in the image/video clips provided.

REFERRING VET

Dr. Ezik

Thank you for this referral. If the clinical or image interpretation does not parallel your findings or



if I can be of any further assistance please contact me.

**DATE**

4/14/23

**Keith Blass, DVM, MS, DACVIM (Cardiology)**

KeithBlass@gmail.com

631-804-5754

**PERFORMED BY:**

Val Shumskaya

**INTERPRETED BY**

Keith Blass, DVM,  
MS, DACVIM  
(Cardiology)

**PATIENT**

Ozzy Silverstein

**SPECIES**

Canine

**BREED**

Aussie Mix

**SEX**

FS

**AGE**

2 y

**WEIGHT**

62.2 lb

**HOSPITAL NAME**

Englewood VC

**REFERRING VET**

Dr. Ezik